



RESEARCH ARTICLE

Testing the Effectiveness of Dayak Onion Extract (*Eleutherine palmifolia* (L) On Mucosa Gastroprotective Activitygumble and Histopathology of Male Mouse (*Mus Musculus*) Which Is Induced AspirinIlham^{1*}, Anna khuzaimah², Yenni yusuf³¹Master Program of Biomedical Sciences, Graduate School, University of Hasanuddin, Makassar, Indonesia² Public Health Faculty, Program of Biomedical Sciences, University of Hasanuddin, Makassar, Indonesia³ Department of Parasitology, Faculty of Medicine, University of Hasanuddin, Makassar, Indonesia**ARTICLE INFO****ABSTRACT**

Received: Jul 19, 2024

Accepted: Aug 28, 2024

KeywordsEleutherine Palmifolia
(eleutherine palmifolia (L))
Aspirin
Gastroprotective
Hispathology***Corresponding Author:**

ilhamanas027@gmail.com

Gastroprotective treatment can use single oral synthetic drugs. Aspirin is a non-steroidal anti-inflammatory drug (NSAID) that is often used to relieve or eliminate pain in the treatment of osteoarthritis and rheumatoid arthritis. In general, people use traditional medicine, along with synthetic medicine. Dayak onions are herbal plants that are widely used to treat pain. This study aims to provide information about the effectiveness of Dayak onion extract (*eleuthero palmifolia* (L) on the gastroprotective activity of the gastric mucosa and histopathology of male mice (*mus musculus*) induced by aspirin and information about the organ protection of mice that experience gastroprotection. Thirty *mus musculus* mice were divided into six groups, namely: normal control group (KN), negative control group (K-), positive control group (K+), and the 1% Dayak onion treatment group (KBD), the 5% Dayak onion treatment group (KBD), the 10% Dayak onion treatment (KBD) 1X1 for four days, and aspirin induction for eight days to create an ulcer mouse model. Treatment was reviewed from body weight and after intervention, as well as gastric histology. After the intervention, the K+ group, control - and Dayak onion extract 1x1, and showed damage to the mice's stomachs (<0.05) compared to the sick group, given control and extract concentrations of 1%, 5%, the best was extract with a concentration of 10%, So the higher the concentration given with the extract, the better, based on the histopathological picture. Dayak onions with an interval of 1 x 1 administration for four days work synergistically in improving the condition of gastric tissue; therefore, giving Dayak onions can be an option as a gastroprotective activity of the gastric mucosa.

INTRODUCTION

Background: Gastritis is an inflammatory condition of the gastric mucosa characterized by epigastric pain, belching, nausea, vomiting, bleeding, and hematemesis. The world mortality rate due to gastritis in hospitalization is 17-21% of cases in 2012. According to WHO (2012), it is 40.8% in Indonesia. The incidence of gastritis in several regions in Indonesia is quite high, with a prevalence of 274,396 cases among 238,452,952 people (Waluyo & Suminar, 2017).

Gastritis can be caused by various things, one of which is NSAIDs (non-steroidal anti-inflammatory drugs). The main effect of NSAIDs on gastritis is inhibition of the COX enzyme (cyclooxygenase). This inhibition results in decreased production of prostaglandins, which are useful for protecting the gastric mucosa. In

gastritis, due to NSAIDs, lymphocyte and PMN (Polymorphonuclear neutrophils) infiltration, lamina propria edema, and blood capillary dilation can be found (Pasaribu et al., 2013).

Aspirin is a non-steroidal anti-inflammatory drug (NSAID) that is often used to relieve or eliminate pain in the treatment of osteoarthritis and rheumatoid arthritis (Wallace & Vong, 2008). Long-term use of NSAIDs can cause side effects on the gastrointestinal tract, such as gastric obstruction, ulcer perforation, and peptic ulcer disease (Targownik et al., 2006; Selak et al., 2010).

Gastroprotective therapy has been shown to prevent the adverse effects of NSAIDs (Kim et al., 2011). Gastroprotective is the ability of certain endogenous factors to protect the gastric mucosa (Meutia, 2018). Synthetic gastroprotective agents include H2 receptor antagonists (cimetidine, ranitidine), proton pump inhibitors (omeprazole, lansoprazole), gastric mucosal protectors (sucralfate, bismuth colloid), and antacids (Targownik et al., 2006; Dipiro et al., 2008).

Various undesirable reactions, such as nausea and dizziness, have been reported with the use of these drugs. Therefore, there is a need to search for drugs that are more potent and have low toxicity (Tundis et al., 2008).

Indonesian people have long known and used medicinal plants as part of their efforts to overcome health problems. Knowledge about medicinal plants is based on experience and skills that have been passed down from generation to generation. Many herbal medicines have been widely accepted in almost all countries in the world. According to the World Health Organization (WHO), countries in Africa, Asia, and Latin America use herbal medicines as a complement to the primary treatment they receive. The advantage of herbal medicine lies in its natural ingredients so that side effects can be minimized. Dayak onion (*Eleutherine palmifolia* (L.) Merr.) is a plant in the Kalimantan forest that is commonly used by the people of the interior of Central Kalimantan as a traditional potion or medicine.



Figure 1. Dayak onion samples (*Eleutherine palmifolia* (L.) Merr.)

METHODS:

Mice (*Mus Musculus*) were divided into six groups, each group consisting of 5 mice (*Mus Musculus*), an M1 NACMC control group, an M2 sick group that was only induced (aspirin), an M3 positive group (omeprazole), a treatment group using dayak onion extract (*Eleutherine palmifolia* (L.) Merr.) M4 extract 1%, M5 extract 5%, and M6 extract 10% oral induction was carried out for eight days, and given medication for four days after induction, histological testing and data processing will be carried out

RESULTS

After induction for eight days using aspirin, weighing and the activity of mice was less active, then the administration of drugs was continued for six days using treatment on M1 NACMC control group, M2 sick group which was only induced (aspirin), M3 positive group (omeprazole), treatment group using dayak onion extract (*Eleutherine palmifolia* (L.) Merr.) M4 extract 1%, M5 extract 5%, M6 extract 10% induction via oral, and on the 13th day, a necropsy was performed, and the stomach organs were taken to make histopathology preparations.

CONCLUSION

It can be concluded that the higher the concentration of Dayak onion extract, the better it is in treating the gastroprotective activity of the gastric mucosa in test animals such as mice.

INTRODUCTION

Gastric ulcer is a very serious condition that has many different clinical manifestations. Most of the literature states that gastric ulcers and duodenal ulcers are in one unit of peptic ulcer, although the pathophysiology of both is different. Untreated gastric ulcers can cause perforation of the upper gastrointestinal tract and be fatal (Idris et al., 2022). The prevalence of peptic ulcers, both gastric ulcers and duodenal ulcers, continues to increase both in Indonesia and in the world. As many as 34.7 million people worldwide experienced it in 2015. The latest statistical data from the World Health Organization (WHO) in 2018 stated that the prevalence of peptic ulcers in Indonesia ranked second in Asia and second in the world. Cases of death from peptic ulcer disease in Indonesia reached 25,559 cases or 1.50% of the total population deaths. The mortality rate of peptic ulcers in Indonesia is 14.95 per 100,000 population, with a percentage based on gender of 17.12% in the male group and 13.00% in the female group (WHO, 2018). Gastritis can be caused by various things, one of which is NSAIDs (non-steroidal anti-inflammatory drugs). The main effect of NSAIDs on gastritis is inhibition of the COX enzyme (cyclooxygenase). This inhibition results in decreased production of prostaglandins, which are useful for protecting the gastric mucosa. In gastritis, due to NSAIDs, lymphocyte and PMN (Polymorphonuclear neutrophils) infiltration, lamina propria edema, and dilation of blood capillaries can be found (Pasaribu et al., 2013). Aspirin is a non-steroidal anti-inflammatory drug (NSAID) that is often used to relieve or eliminate pain in the treatment of osteoarthritis and rheumatoid arthritis (Wallace & Vong, 2008). Long-term use of NSAIDs can cause side effects on the gastrointestinal tract, such as gastric obstruction, ulcer perforation, and gastric ulcer disease (Targownik et al., 2006; Selak et al., 2010). Gastroprotective therapy has been shown to prevent the adverse effects of NSAIDs (Kim et al., 2011).

Gastroprotective is the ability of certain endogenous factors to protect the gastric mucosa (Meutia, 2018). Synthetic gastroprotective agents include H₂ receptor antagonists (cimetidine, ranitidine); proton pump inhibitors (omeprazole, lansoprazole); gastric mucosal protectors (sucralfate, bismuth colloid); and antacids (Targownik et al., 2006; Dipiro et al., 2008). Various undesirable reactions, such as nausea and dizziness, have been reported in the use of these drugs. Therefore, it is necessary to find drugs that are more potent and have low toxicity (Tundis et al., 2008). Indonesian people have long known and used medicinal plants as an effort to overcome health problems. Knowledge about medicinal plants is based on experience and skills that have been passed down from generation to generation. Many herbal medicines have been widely accepted in many countries around the world.

Dayak onion (*Eleutherine palmifolia* (L.) Merr.) is a plant in the Kalimantan forest that is commonly used by the people of the interior of Central Kalimantan as a herbal medicine or traditional medicine. In general, the parts of the plant used are the bulbs and leaves. Tables 3, 4, 5, 6, 7, and 8 show the average data on the level of weight loss in mice. The weight of the body in the 3rd table is the normal control, with the first mouse on days 1-8 having a normal weight, and then on days 9-12 the body weight remains consistent with 29 grams. The weight of the body in the 4th table the second mouse on days 1-8 has an irregular and abnormal weight during aspirin induction, and then on days 9-12 without treatment with a weight brought to normal with 18 grams, in the 5th table mouse 3 on days 1-8 has an irregular and abnormal weight during aspirin induction, and then on days 9-12 the body weight begins to return to normal after treatment using the synthetic drug omeprazole, with a final weight of 30 grams, in the 6th table, the third mouse on days 1-8 has an irregular and abnormal weight during aspirin induction, and then on days 9-12 the body weight begins to return to normal after treatment using Dayak onion extract with a concentration of 1%, with a final weight of 20 grams of mice, in table 7, the second mouse on days 1-8 had an irregular and abnormal weight during aspirin induction, and then on days 9-12 the body weight began to return to normal after treatment using Dayak onion extract with a concentration of 10%, with a final weight of 28 grams of mice, in table 8, the third mouse on days 1-8 had an irregular and abnormal weight during aspirin induction, and

then on days 9-12 the body weight began to return to normal after treatment using Dayak onion extract with a concentration of 5%, with a final weight of 30 grams of mice. This presentation shows the use of Dayak onions as a herbal medicine as a gastroprotective. Dayak onions play a role in reducing stress and increasing prostaglandin production in the gastric mucosa, which will reduce H⁺ ion secretion and increase mucus production because they have quite strong antioxidant activity and Flavonoid Compounds found in Dayak onion bulbs.

METHODS

Place and preparation of dayak onion samples

This study was conducted in the phytochemistry laboratory, pharmacology toxicology, faculty of pharmacy, Hasanuddin University, Makassar, in March 2024, and the Dayak onion samples were taken in Kalimantan; the maceration method was used to obtain a thick extract in the Dayak onion samples, Dayak onions to be used were previously weighed and blended until smooth until they form a powder. Then, the resulting powder is dried for one week. The drying process is done by placing it in an open place with good air circulation and not exposed to direct sunlight. If the drying process is carried out at a temperature too high or by being exposed to direct sunlight, it can damage its active components. After being dried and in powder form, it is then soaked in 96% ethanol with a volume twice the volume of the Dayak onion powder for one day, then filtered to obtain liquid from the soaking results. The filtered results are evaporated with a rotary evaporator to obtain the extract.

Phytochemical screening of dayak onion samples (*Eleutherine palmifolia* (L.) Merr.)

After obtaining the thick extract of dayak onion, phytochemical screening was carried out, and ensuring the secondary metabolite compounds contained in dayak onion by looking at the presence of alkaloids, flavonoids, triterpenoids, tannins, and saponins, Anova analysis showed a significance value of $p > 0.05$ in each treatment group, so it can be concluded that there is no significant effect between treatment groups when viewed from body weight parameters. The Kruskal-Wallis H test was also carried out to see the difference in body weight H-to 0 (before intervention) obtained a value of $p = 26.67$ ($p > 0.05$), which showed no difference between groups, but after the intervention on the 12th day according to the treatment group obtained a value of $p = 22.10$ ($p > 0.05$) which showed no significant difference between groups. However, body weight Table 6 shows that there was an initial decrease in body weight during aspirin induction and began to increase on the 9th to 12th day after treatment using dayak onion extract. Administration of single dayak onion extract affected the improvement of the histopathological picture of the stomach of mice that had been induced by aspirin. Dayak onion extract The most effective effect of dayak onion at the highest concentration on the histopathological picture of the stomach was the 10% concentration group.

For the alkaloid test, Dayak onion extract was added with 2 ml of HCl and then divided into 3 test tubes. Three drops of Mayer, Wagner, and Dragendorff reagents

were added to each test tube.

For the Flavonoid test, the extract was added with 0.2 g of Mg powder and then added with 5 ml of concentrated HCl. If a red, orange, or yellow color is formed, it indicates flavonoids. **Triterpenoid test:** Extract was added with 2 ml of chloroform, two drops of glacial acetic acid, and two drops of H₂SO₄. If a dark blue or blackish-green color is formed, it indicates triterpenoids.

Tannin test: Extract was added with 5 ml of 1% FeCl₃ and then shaken. If a dark blue or black color is formed for 1 minute, it indicates tannins.

Saponin test: Extract was added with 10 ml of hot water, then shaken for 1 minute, observed for foam, then added 2 N HCl, observed for up to 5 minutes. Saponin indication is marked by constant foam that persists for 5 minutes after the addition of 2 N HCl.

Acclimatization and Preparation of Mice Model (*Mus musculus*)

A total of 25 male mice were divided into six groups, each group consisting of 5 mice. The selected male mice (*Mus musculus*) were 3-4 months old and had an average weight of 25 grams. The mice were placed in cages with a base of rice husks and covered with wire. The feed given was in the form of pellets, and drinking water was given ad libitum; M1 was the NACMC control group, M2 was the sick group that was only induced (aspirin), M3 was the positive group (omeprazole), the treatment group used dayak onion extract (*Eleutherine palmifolia* (L.) Merr.) M4 extract 1%, M5 extract 5%, M6 extract 10%, Sonde was needed when inserting the extract into the stomach of the mice. This treatment was carried out for 12 days. On the 13th day, a necropsy was performed, and the stomach organs were taken to make histopathology preparations.

Gastric histopathology

After taking the stomach from the mice, experts from the pathology department of FKH UNAIR interpreted it.

RESULTS

Phytochemical screening of dayak onion samples (*Eleutherine palmifolia* (L.) Merr.)

In the phytochemical screening process of secondary metabolites in Dayak onion extract (*Eleutherine palmifolia* (L.) Merr.), the results can be found in Table 1

Table 1. Secondary metabolite content of dayak onion (*Eleutherine palmifolia* (L.) Merr.)

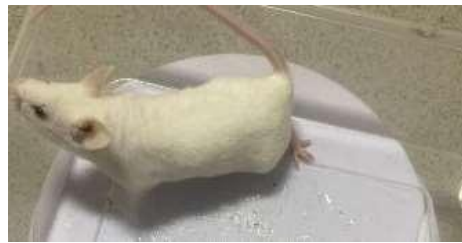No	Chemical content	reactor	Test results
1	alkaloid	HCL+ mayer,wagner,dragendroff	(++)
2	flavonoid	Serbuk Mg, HCL	(+++)
3	tannin	FeCl3	(++)
4	saponin	Aquadest, Hcl2N	(++)
	Five triterpenoid	Chloroform, H2So4	

(+)Description = (+++) : many, (++) : moderate, (+) = few, (-) : no

Histopathology of mice stomach

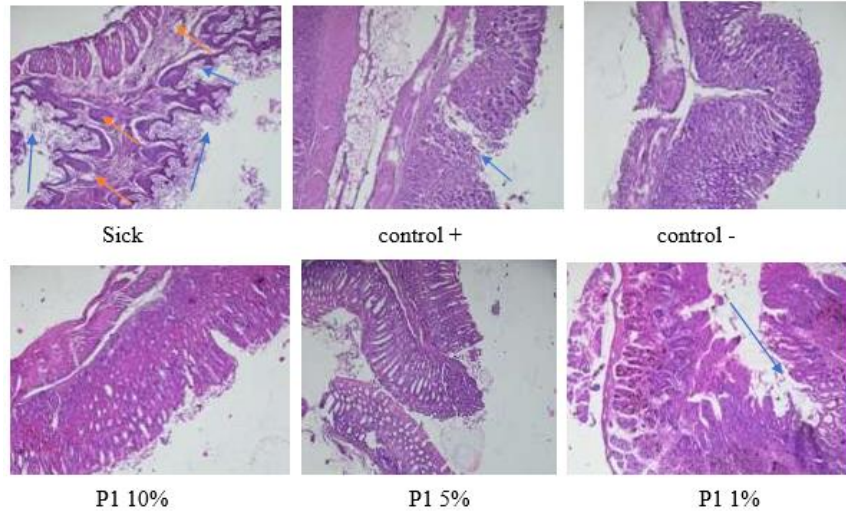
Table 2. Level of stomach damage in 6 groups of mice

Samples	of many erosions	of cells that inflame	blood vessels
Sick	3	3	0
control +	1	0	0
control -	0	0	0
P1 10%	0	0	0
P2 5%	0	0	0
P3 1%	1	0	0



Page 2 test animal Male Mice (*Mus Musculus*) Histopathology of mouse stomach

Histopathology of mouse stomach



Description: blue arrow: erosion, orange arrow: inflammatory cells

Group	N	Aspirin Induction	Treatment	Significance
		(mean + SD)	(mean + SD)	
K1	5	27.10+0.91	25.15+1.70	0.054
K2	5	22.65+2.02	21.75+0.79	0.382
K3	5	22.10+2.06	25.65+1.19	0.010
K4	5	21.70+1.60	23.42+1.74	0.142
K5	5	21.55+0.87	22.47+0.66	0.096
K6	5	22.10+2.06	26.67+1.70	0.005

Measurement of test animal weight, induction treatment, and medication

Test animal group (1)	Aspirin Induction			Normal									
	1	2	3	4	5	6	7	8	9	10	11	12	13
Day/gram	1	2	3	4	5	6	7	8	9	10	11	12	13
Mouse 1	28	28	28	25	28	25	25	28	29	28	27	29	surgery
Mouse 2	37	35	21	21	20	25	21	22	27	27	20	27	

Mouse 3	31	30	24	22	21	24	25	26	28	29	25	28	
Mouse 4	31	28	25	24	20	25	25	24	22	20	24	26	
Mouse 5	31	30	23	20	29	28	25	26	21	24	25	28	

Test animal group (2)	Aspirin Induction(sick)			Without treatment									
Day/gram	1	2	3	4	5	6	7	8	9	10	11	12	13
Mouse 1	22	22	21	20	20	21	22	24	25	25	26	28	
Mouse 2	25	20	20	19	20	22	28	27	28	29	28	18	surgery
Mouse 3	26	25	21	20	25	25	28	27	29	25	29	28	
Mouse 4	25	23	21	19	20	20	21	25	26	27	28	28	
Mouse 5	27	21	20	18	20	21	25	28	28	29	25	28	

Test animal group (3)	Aspirin Induction			Treatment (omeprazole)									
Day/gram	1	2	3	4	5	6	7	8	9	10	11	12	13
Mouse 1	27	20	29	25	24	20	19	25	26	28	20	29	
Mouse 2	22	20	19	20	25	27	28	29	31	20	21	28	
Mouse 3	24	20	23	25	26	21	25	24	20	28	27	30	surgery
Mouse 4	24	19	20	23	24	25	28	29	25	25	24	29	
Mouse 5	24	20	19	19	24	25	25	28	28	29	27	30	

Test animal group (4)	Aspirin Induction			Treatment (1% extract)									

Day/gram	1	2	3	4	5	6	7	8	9	10	11	12	13
Mouse 1	24	25	25	24	25	23	24	26	28	29	28	20	
Mouse 2	22	21	22	21	25	24	27	22	20	20	28	20	
Mouse 3	25	20	20	19	24	23	28	25	28	28	20	20	surgery
Mouse 4	24	20	19	19	24	15	20	19	20	19	25	24	
Mouse 5	25	19	20	20	23	26	21	25	25	20	21	25	

Test animal group (5)			Penguin Aspirin							Treatment (5% extract)			
Day/gram	1	2	3	4	5	6	7	8	9	10	11	12	13
Mouse 1	25	24	21	20	24	20	25	24	25	20	20	28	
Mouse 2	24	19	20	20	19	20	20	21	19	20	25	28	surgery
Mouse 3	29	20	20	19	20	21	20	24	25	21	20	29	
Mouse 4	21	20	21	20	24	25	20	25	20	20	21	28	
Mouse 5	24	22	21	21	20	24	20	21	20	24	25	24	

Test animal group (6)			Aspirin Induction							Treatment (10% extract)			
Day/gram	1	2	3	4	5	6	7	8	9	10	11	12	13
Mouse 1	28	25	20	20	21	20	25	20	25	25	24	28	
Mouse 2	25	21	20	20	19	20	21	20	20	24	24	25	
Mouse 3	28	24	25	20	20	19	21	20	20	25	29	30	surgery
Mouse 4	25	19	21	20	20	24	25	25	21	20	20	25	
Mouse 5	27	25	20	25	19	20	25	20	21	21	20	25	

DISCUSSION

Dayak onion bulbs (*Eleutherine palmifolia* (L.) Merr) contain secondary metabolite compounds of the flavonoid group; in addition, Dayak onion bulbs (*Eleutherine palmifolia* (L.) Merr) also contain secondary metabolite compounds of the naphthoquinone group and its derivatives such as elecanacin, eleutherin, eleuthero, eleuthero, eleuthero, eleuthosid,

Dayak onion is one of the feed additives that contain complete active compounds; these compounds include flavonoids, alkaloids, steroids, glycosides, phenolics, saponins, and tannins. Flavonoids have anti-cancer benefits and are also antiviral, anti-inflammatory, and anti-free radicals; dayak onion bulbs (*Eleutherine palmifolia* (L.) Merr) are widely cultivated and even grow wild in Kalimantan, the content of secondary metabolites found in Dayak onionbulbs (*Eleutherine palmifolia* (L.) Merr).

Flavonoids are secondary metabolite compounds that can increase the production of prostaglandins in the gastric mucosa, which will reduce the secretion of H⁺ ions and increase mucus production. The activity of flavonoids mentioned above is expected to reduce gastric inflammation, cell injury response, and the number of inflammatory cell infiltrations in the gastric mucosa.

In Table 1, after conducting phytochemical screening of secondary metabolites in Dayak onionbulb extract (*Eleutherine palmifolia* (L.) Merr), positive results were obtained containing many flavonoid compounds, moderate alkaloids, moderate tannins, moderate saponins, fewer triterpenoids, with the results obtained, the potential is great as a gastroprotective activity against the gastric mucosa of mice which will reduce H⁺ ion secretion and increase mucus production.

In table 2 and the histopathology results of the stomach of mice show that in the sick preparation, there is erosion, inflammation, and excessive dilation of blood vessels that have been induced by aspirin; in the histopathology preparation of the positive control (omeprazole), there is 1 part with signs of erosion, inflammation, and dilation of blood vessels, in the negative control preparation without treatment there is no sign of erosion, inflammation, and dilation of blood vessels, in the P10% preparation there is no sign of erosion, inflammation, and dilation of blood vessels, in the preparation, in the P5% preparation there is no sign of erosion, inflammation, and dilation of blood vessels, in the preparation, in the P1% preparation there is 1 part of erosion, inflammation, and dilation of blood vessels, in the preparation.

Our study evaluating the use of shallot extract (*Eleutherine palmifolia* (L.) Merr) as a gastroprotective activity of the gastric mucosa undoubtedly has many aspects that require further exploration to realize its full potential. Future studies should conduct additional parameter tests that will aim to elucidate the beneficial effects of shallot bulbs (*Eleutherine palmifolia* (L.) Merr) on health; considering that recent studies can specifically address the mechanisms of flavonoids as gastroprotective to the gastric mucosa, researchers can also explore the long-term effects of consuming shallot bulbs (*Eleutherine palmifolia* (L.) Merr), this can provide valuable information regarding the sustainability and long-term safety of shallot bulbs (*Eleutherine palmifolia* (L.) Merr) for gastroprotection of the gastric mucosa.

CONCLUSION

The higher the concentration of dayak onion extract, the better and more efficacious as a gastroprotective agent for the gastric mucosa of mice, so it has the potential to be a functional herbal medicine in preventing peptic ulcers

Acknowledgment

The author would like to thank the Hasanuddin University Postgraduate School, parents, and the Ministry of Education and Culture's superior scholarships that have supported the course of this research, friends, and all those involved in helping this research.

Author Contributions

Kk and il have been involved in planning, compiling manuscripts, data processing, planning, analysis, images, interpretation of results, preparation of manuscript drafts, sm, an. nr, k, and ewere involved in reviewing the implementation of the research and writing the manuscript of this research.

REFERENCES

- Lilyawati, S. A., N. Fitriani, and F. Prasetya. "The Effect of Gastric Ulcer Induction Using Aspirin on Gastric Mucosal Tissue Damage in Mice." 2019.
- Seja, Yulita, Mirhansyah Ardana, and Fika Aryati. "The Effect of Temperature and Storage Time of Dayak Onion Extract (*Eleutherine americana* L (Merr)) on Antibacterial Activity." 2018.
- Amrulloh, Fathan Muhi, and Nurul Utami. "The Relationship between NSAID Consumption and Gastritis." (2016)
- Meutia, Rena, et al. "The Effectiveness of Honey as a Gastroprotective Agent in Aspirin- Induced White Rats Based on Histopathology Results." (2022).
- Sumbayak, Erma Mexcorry, and Nia Vebriyani. "The Effect of Dayak Onion (*Eleutherine palmifolia*) Infusion on Microscopic Images of Mice Kidneys Induced by CCl₄ (Carbon Tetrachloride)." (2019)
- Puspadewi, Ririn, Putranti Adirestuti, and Rizka Menawati. "The efficacy of Dayak onion bulbs (*Eleutherine palmifolia* (L.) Merr.) as an antimicrobial skin herb." (2013)
- Silitonga, Lisnawaty, Satrio Wibowo, and Metami Yulina Sirait. "The Effect of Dayak Onion Extract (*Eleutherine* et al..) in Drinking Water on Broiler Chicken Performance." (2022)
- Prayitno, Budi, and Bayu Hari Mukti. "Optimization of Dayak Onion Potential (*Eleutherine* Sp.) as an Alternative Medicine." (2018)
- Maulida, Shofiatun; Ririn Lispita, Wulandari. Gastroprotective Effect of Ethanol Extract of Yellow Pumpkin Fruit (*Cucurbita Moschata* (Duch.) Poir) in Male Wistar Rats Induced by Aspirin. 2020. PhD Thesis. Wahid Hasyim University.
- VAN LAAR, Mart, et al. Pain treatment in arthritis-related pain: beyond NSAIDs. *The Open Rheumatology Journal*, 2012
- LIE, Jason Gunawan, et al. The Role of Proton Pump Inhibitors in Preventing Gastrointestinal Bleeding in Patients Taking Antiplatelets. *Health Information: Research Journal*, 2023.
- Yolla Margaretha, Popo Suryana, (2023). The Effect of Market Orientation, Entrepreneurial Orientation, and Learning Orientation on Marketing Innovations and their Implications on the Marketing Performance of Micro Actors in Bandung Metropolitan Area. *Pakistan Journal of Life and Social Sciences*. E-ISSN: 2221-7630; P-ISSN: 1727-4915, Pak. j. life soc. Sci. (2023), 21(1): 478-498. https://www.pjlss.edu.pk/pdf_files/2023_1/478-498.pdf