

## Effect of Vitamin E and Selenium as Immunomodulators on Induced Aflatoxicosis in Broiler Birds

Abeera Mubarak, Asif Rashid, Imtiaz Ahmad Khan and Azhar Hussain  
Veterinary Research Institute, Ghazi Road Lahore Cantt-Pakistan

### Abstract

**Mycotoxigenesis, a serious problem to commercial poultry, is incurable; however certain group B vitamins, vitamin E and selenium are capable of reducing and facilitating the decomposition and detoxification of mycotoxin within the body. In present study, effect of vitamin E and selenium was studied in broiler birds with induced aflatoxicosis. Five groups of broilers birds were reared and feed differently i.e., Group B was fed with vitamin E and selenium along with aflatoxin B<sub>1</sub> mixed feed, group C was fed with vitamin E and aflatoxin B<sub>1</sub> mixed feed, group D was fed with selenium and aflatoxin B<sub>1</sub> mixed feed and group E was fed only aflatoxin B<sub>1</sub> mixed feed while group A was kept as control. The study was conducted for three weeks and concluded that vitamin E and selenium in combination can act as immunomodulator even then the birds were challenged with aflatoxin B<sub>1</sub>.**

**Keywords:** Mycotoxigenesis, vitamin E, selenium immunomodulator

### Introduction

Mycotoxins are the metabolic products of toxigenic fungi, released during the growth in various feedstuffs. Aflatoxins are the most common mycotoxins, widely prevalent in different feed commodities. These toxins are considered to be most important because of wide range of host susceptibility, immunosuppression, hepatotoxicity and heat stable properties of aflatoxin and are potential hazards affecting the poultry industry resulting in heavy economic losses (Mundas and Rao, 2001).

Aflatoxins are proved to suppress the immune response of the birds leading to persistence of Newcastle disease in broiler flock even after vaccination (Mani *et al.*, 2001). Various findings strongly suggested the enhancement of immune response due to vitamin E supplementation. Vitamin E converts arachidonic acid into prostaglandin,

which plays an important role in enhancement of immune response (Balker, 1993). Selenium has also been reported to improve the immune response in broilers fed with aflatoxin contaminated diets (Perozo and Rivera, 2003).

Considering the importance of vitamin E and selenium in immunity, a project was designed to check the immune response of broiler birds supplemented with vitamin E and selenium alone or in combination on induced aflatoxicosis.

### Materials and Methods

#### Birds

Fifty, day old broiler chicks were reared and provided balance feed. The birds were vaccinated against Newcastle Disease, Hydro Pericardium Syndrome and Infectious Bursal Disease on 7th, 18th and 28th days of age, respectively.

#### Production and estimation of Aflatoxin B<sub>1</sub>

Aflatoxin was produced by *Aspergillus flavus*. Briefly, 25 gm of sample was transferred to sabouraud's medium. The sample particles were dispersed throughout the medium by shaking. The samples was incubated at 30°C and observed daily for the development of growth while the estimation of aflatoxin (part per billion) obtained from isolated culture was carried out at Department of food and Nutrition, University of Veterinary and Animal Sciences, Lahore, by thin layer liquid chromatography (Anonymous, 1990).

#### Experimental set up

The birds were divided into five groups, each comprising of ten birds i.e. A, B, C, D and E. Group A was taken as control. The birds of group B were fed with Vitamin E and Se along with aflatoxin B<sub>1</sub> mixed feed. Group C was fed with vitamin E and aflatoxin B<sub>1</sub> mixed feed. Group D was treated with Se and aflatoxin B<sub>1</sub> mixed feed and group E was fed only aflatoxin B<sub>1</sub> mixed feed. Aflatoxin B<sub>1</sub> was given 80 parts per billion (ppb) while Vitamin E and Se (Sodium Selenite) were given at the rate of 200 mg and 1mg per kg of feed respectively.

The birds were kept under observation for three weeks. Their morbidity and mortality was recorded on regular basis. After 3 weeks, the remaining birds were scarified and their organs were collected for histopathology. Blood of normal, sick and scarified

---

**Correspondence Author:** Abeera Mubarak,  
Veterinary Research Institute,  
Ghazi Road Lahore Cantt -Pakistan.

birds was collected for leukocytes count and antibody titre against Newcastle Disease was determined with the help of haemagglutination inhibition test (Brugh, 1997). The data obtained in the experiment was statistically analyzed. (Steel *et al.*, 1997).

## Results and Discussion

### Clinical signs

Group A was selected as control throughout the experiment. The birds of group B remained normal, no mortality was seen. In group C, no clinical signs were observed in first two weeks, while in third week, three birds showed sluggishness, ruffled feathers and impaired growth. One bird was died in group C. In group D, no clinical signs were observed in first week but in second and third weeks, some birds had ruffled feathers and enteritis. Mortality was observed in third week and three birds died. In group E, all the birds showed ruffled feathers, enteritis with undigested feed particles in the faeces within second and third week of study. Local haemorrhages and impaired growth in some birds was also observed. This is in accordance to Afzal and Saleem (2004) who observed significant mortality in broilers when given aflatoxin contaminated feed at the level of 78 ppb.

### Gross lesions

Grossly, the birds of aflatoxin B<sub>1</sub> fed group showed enlarged liver, kidneys and atrophied bursa. Liver showed petechiation and discoloration. Similar lesions were observed by Mundas and Rao (2001) and Prakash *et al.* (2002). Spleen was also enlarged and discolored. Haemorrhages in the subcutaneous tissue and fragile bones were observed. These results coincide with the observation of Shivachandra *et al.* (2003), but Nataraja *et al.* (2003) observed atrophied

spleen in aflatoxin B<sub>1</sub> fed birds, which might be due to trichothecenes (T<sub>2</sub>) toxicosis.

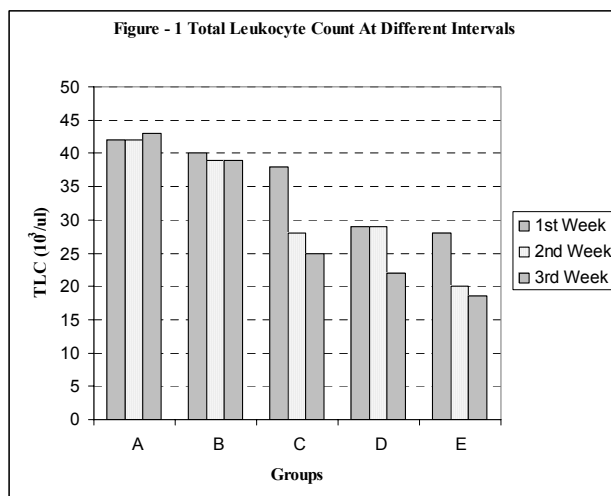
Gross changes in the organs of other groups were slight as compared to group E but fragile bones and subcutaneous haemorrhages in some birds of group C and D were observed. In group B, all above said lesions were not present but on postmortem, some carcasses were found congested.

### Histopathology

Aflatoxin B<sub>1</sub> fed birds at the level of 80 ppb showed haemorrhagic liver with hyperplasia of bile duct epithelium. Depletion of lymphoid follicles in bursa of fibracious and spleen were observed along with sloughing of bursal epithelium. In kidneys, cellular swelling and distension of proximal convoluted tubules were present. Same lesions were reported by Gupta and Amarjit (2003), Shivachandra *et al.* (2003) and Mundas and Rao, (2001). Other groups given vitamin E and Se in combination or alone showed less severe lesions as compared to Aflatoxin B<sub>1</sub> fed birds. Similar findings were reported by Srivani *et al.* (2003) who observed congested liver and depleted lymphoid follicle in the bursa of fibracious in aflatoxin B<sub>1</sub> fed broiler chicks.

### Total Leukocytes count (TLC)

After first week, there was no significant difference in control group and group B as shown in Figure -1. In second and third week, significant difference between control group and group E was present ( $P < 0.01$ ). TLC was significantly decreased in group E as compared to other groups after third weeks. TLC was higher in group B in all the three weeks showing that combination of vitamin E and Se played a significant role in neutralizing aflatoxin effects rather than using them alone. These observations were in line with Flora and Malathy (2004).



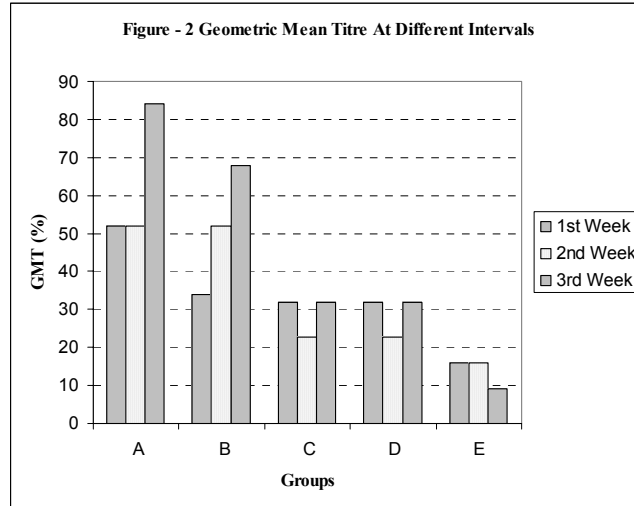
Significant Difference  $P < 0.01$

**Geometric Mean Titre (GMT)**

Antibody titre against Newcastle Disease was determined by hemagglutination inhibition test. A decrease in antibody level was present in group E as compared to other groups as shown in Figure -2. The results showed that vitamin E and Se combination can decrease the adverse effects of aflatoxin B<sub>1</sub> rather

than used alone or not used. The results concur with the findings of Mani *et al.* (2001).

In conclusion, vitamin E and selenium, in combination can act as immunostimulators and protects the broiler birds when challenged with aflatoxin.



**Acknowledgement**

The authors are thankful to Prof. Dr. Talat Naseer Pasha, Department of Food and Nutrition, University of Veterinary and Animal Sciences, Lahore, Pakistan for providing the necessary facility to carry out the work.

**References**

Afzal, M, and Z. Saleem, Effect of addition of a mycotoxin detoxifier in poultry feed containing different levels of aflatoxins on the performance of broilers. *Asian-Australian J. of Ani. Sci.*, 2004. 17. 990-994.

Anonymous., Official method of analysis. 14th Ed. Association of official analytical chemists. Arrington, Virginia. U.S.A. 1990.

Balker, S., Role of vitamin E in enhancing in immune response. *Proceeding of 2nd Asian /Pacific poultry health*, Australia. 1993.

Brugh, M., 1997. A simple method for recording and analyzing serological data. *Avian Dis.*, 22:362-365.

Gupta, K., and S. Amarjit, Experimental studies on aflatoxicosis, infectious bursal disease and their interaction in broiler chicks. *Ind. J. Vet. Pathology.*, 2003. 27:5-7.

Flora, P., and J. Malathy, Effect of aflatoxin B<sub>7</sub> on phosphorous, alkaline phosphate and some haematological parameters on white leghorn

breed (*Gallus gallus domesticus*). *Toxi. Int.*, II 2004. 1: 33-41.

Mani, K., K. Sundaresan, and K. Viswanathan, Effect of immunomodulators on the performance of broilers in aflatoxicosis. *Ind. Vet. J.*, 2001. 78: 1126-1129.

Mundas, S., and D. G. K. Rao, Histological changes in liver by aflatoxin and fanvelerate treated broiler birds. *Ind. Vet. J.*, 2001.78:1152-1153.

Nataraja, T. H., H. D. N. Swam, S. K. Vijayasarithi, B. S. Kumar, and G. C. Prakash., Pathology of lymphoid organs of broiler chickens with aflatoxicosis and T-2 toxicosis. *Ind. J. Ani. Sci.*, 2003.73:1342-1343.

Perozo, F and S. Rivera, Effect of aflatoxin B<sub>1</sub> exposure and selenium supplementation on immune response in broilers. *Ind. Vet. J.*, 2003. 80 : 1218-1221.

Prakash, G. C., T. S. Nalini, S. K Vijayasarithi, and B. Umakantha, Pathomorphological studies to evaluate the effect of combination of aflatoxin and ochratoxin in broiler chickens. *Ind. J. Ani. Sci.*, 2002. 72: 418-420.

Shivachandra, S. B., R. L. Sah, S. D. Singh, T. S Johri, and K. Manimaran, Pathobiochemical and immunological changes in experimental aflatoxicosis. *Ind. J. Poultry Sci.*, 2003. 38.:137-141.

Srivani, M., Y. Anjaneyulu, A. S. Rao, B. J. R. Sarma, and M. V. L. N. Raju, Efficacy of Immunomodulators on induced aflatoxicosis in broiler chicks - a pathological study. *Ind. J. Vet. Path.*, 2003. 27:27-29.

Steel, R. G. D., J. H. Torrie, and D. Dickey, *Principles and Procedures of Statistics. A Biometrical Approach*, 3rd Ed. McGraw Hill Book Co New York, USA. 1997.